

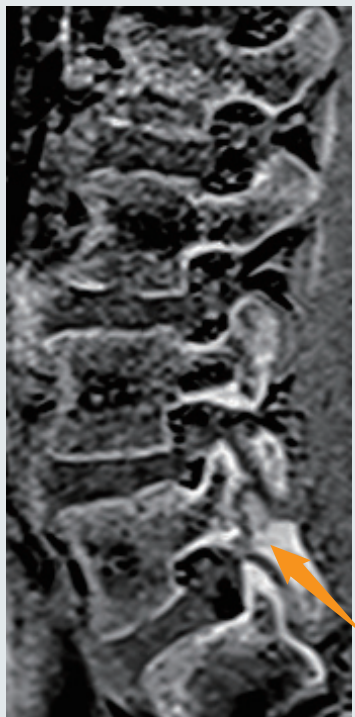
MRI最新技術CT like imageにより 腰椎分離症の評価が可能

特徴

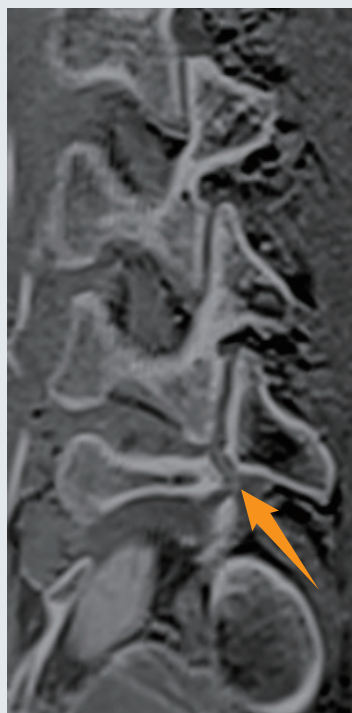
- 被ばくがない(特に若年者に有用)
- 短期間で何回も検査可能(短期でのフォローアップ検査実施)
- CTでは評価が難しい病期(特に超初期)評価はMRIが有用
- 腰椎以外の部位も撮像可能

CT like imageを用いた腰椎分離症評価

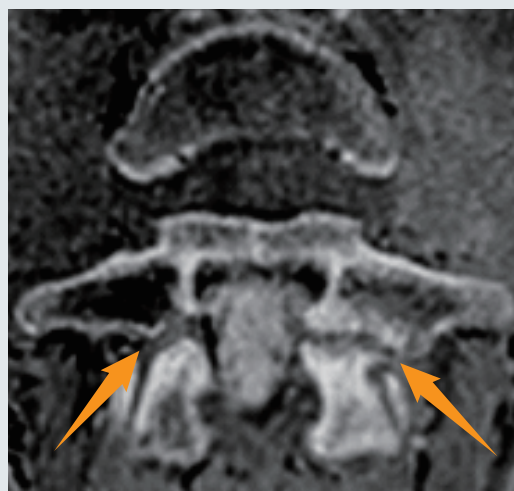
CT like image



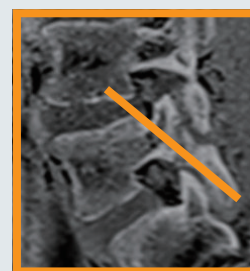
Lt-Sagittal



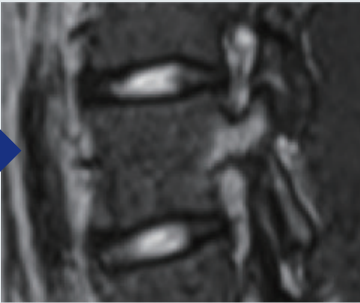
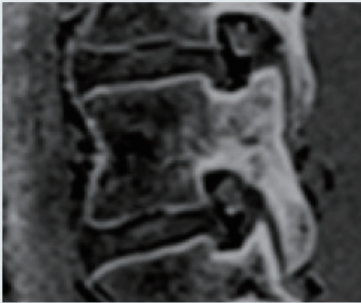
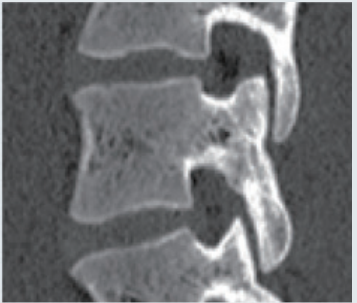
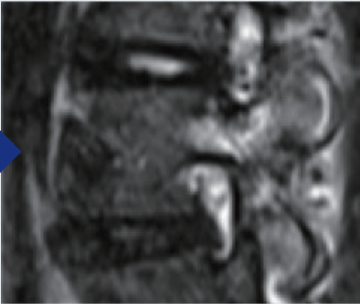
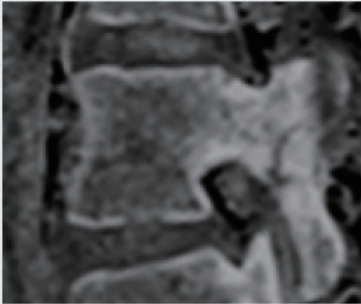
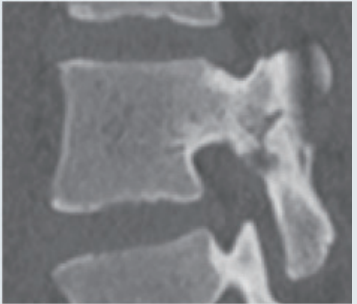
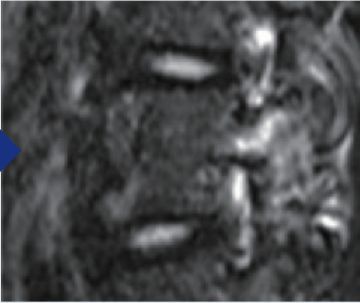
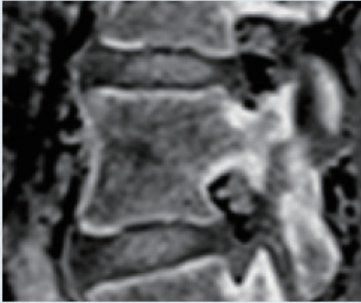
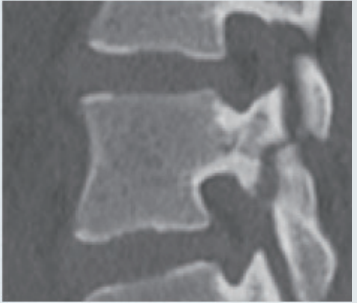
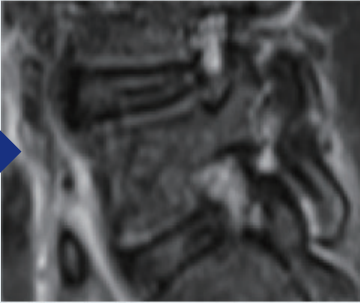

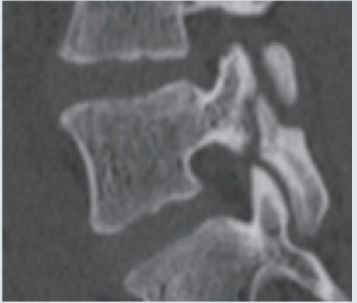
Rt-Oblique



L5 Oblique-Axial



小児における腰椎分離症症例

	STIR	CT like image	CT
超初期			
初期			
進行期前期			
進行期後期			
終末期	